



Transient alcohol craving suppression by rTMS of dorsal anterior cingulate: An fMRI and LORETA EEG study[☆]

Dirk De Ridder^{a,*}, Sven Vanneste^a, Silvia Kovacs^b, Stefan Sunaert^b, Geert Dom^c

^a Brai²n, TRI & Department of Neurosurgery, University Hospital Antwerp, Belgium

^b Department of Radiology, University Hospital Leuven, Belgium

^c Collaborative Antwerp Psychiatry Research Institute, Antwerp University, Belgium

ARTICLE INFO

Article history:

Received 4 October 2010

Received in revised form 24 March 2011

Accepted 24 March 2011

Keywords:

EEG

sLORETA

Functional connectivity

Phase synchronization

Substance abuse

rTMS

fMRI

ABSTRACT

It has recently become clear that alcohol addiction might be related to a brain dysfunction, in which a genetic background and environmental factors shape brain mechanisms involved with alcohol consumption. Craving, a major component determining relapses in alcohol abuse has been linked to abnormal activity in the orbitofrontal cortex, dorsal anterior cingulate cortex (dACC) and amygdala. We report the results of a patient who underwent rTMS targeting the dACC using a double cone coil in an attempt to suppress very severe intractable alcohol craving. Functional imaging studies consisting of fMRI and resting state EEG were performed before rTMS, after successful rTMS and after unsuccessful rTMS with relapse. Craving was associated with EEG beta activity and connectivity between the dACC and PCC in the patient in comparison to a healthy population, which disappeared after successful rTMS. Cue induced worsening of craving pre-rTMS activated the ACC-vmPFC and PCC on fMRI, as well as the nucleus accumbens area, and lateral frontoparietal areas. The nucleus accumbens, ACC-vmPFC and PCC activation disappeared on fMRI following successful rTMS. Relapse was associated with recurrence of ACC and PCC EEG activity, but in gamma band, in comparison to a healthy population. On fMRI nucleus accumbens, ACC and PCC activation returned to the initial activation pattern. A pathophysiological approach is described to suppress alcohol craving temporarily by rTMS directed at the anterior cingulate. Linking functional imaging changes to craving intensity suggests this approach warrants further exploration.

Crown Copyright © 2011 Published by Elsevier Ireland Ltd. All rights reserved.

Almost everyone in the Western world has ever used alcohol in his/her life (92%) [5]. Alcohol dependence and/or abuse are a prevalent problem, affecting 8.5% of US citizens [8]. Alcohol dependence, also known as alcoholism, is a condition characterized by impaired control over drinking, compulsive drinking, preoccupation with drinking, tolerance to alcohol and/or withdrawal symptoms. Thus, in alcohol dependence there is a persistent use of alcohol despite problems related to the use of the substance. Alcohol abuse is a condition that is characterized by failure to fulfill major role obligations at work, school, or home, interpersonal social and legal problems, and/or drinking in hazardous situations.

It has recently become clear that alcohol addiction might be related to a brain dysfunction, in which a genetic background and environmental factors shape brain mechanisms involved with alco-

hol consumption [11]. The dopaminergic and opioidergic reward system is the major player in the pathophysiology of alcohol addiction [11]. Craving, a major component determining relapses in alcohol abuse has been linked to abnormal activity in the orbitofrontal cortex, dorsal anterior cingulate cortex (dACC) and amygdala [11]. The involvement of the anterior cingulate in alcohol craving has been demonstrated by positron emission tomography [12], and functional magnetic resonance imaging (fMRI) [21] which is modulated by the dopamine D2 receptor TAQ1A allele [13]. The ACC, extended to the posterior cingulate cortex (PCC), striatum and posterior insula is also related to relapses in alcohol abuse [20]. The PCC involvement in alcohol dependency and relapse has also been shown with PET scan [20]. Furthermore the anatomical connectivity as measured by diffusion tensor imaging between the ACC and PCC in alcohol dependency is decreased along the superior cingulate fibers in contrast to the inferior cingulate bundle, which remains intact [16].

Transcranial magnetic stimulation (TMS) is a non-invasive technique used to modulate activity and connectivity in the brain [18]. Typically TMS is applied with a figure-of-eight coil. TMS modulates the superficial cortical areas directly but has an indirect effect on remote areas functionally connected to the stimulated area.

[☆] Disclaimer: The authors have no financial interest in any of the methods or treatments described in this manuscript.

* Corresponding author. Brai²n, University Hospital Antwerp, Wilrijkstraat 10, 2650 Edegem, Belgium. Tel.: +32 821 33 36; fax: +32 3 825 25 28.

E-mail addresses: dirk.de.ridder@ua.be (D. De Ridder),

sven.vanneste@ua.ac.be (S. Vanneste).

URL: <http://www.brai2n.com> (D. De Ridder).

Repetitive TMS (rTMS) has been used to reduce craving in nicotine [1] and cocaine [17] addiction, or to reduce cigarette consumption without a decrease in craving [6]. A recent study demonstrated that rTMS can suppress alcohol craving as well [15]. These studies were performed using a figure-of-eight coil targeting dorsolateral prefrontal cortex (DLPFC) [17]. rTMS of the DLPFC is known to increase the release of dopamine in the nucleus accumbens [7], caudate nucleus [10] and to modulate dopamine release in the subgenual anterior cingulate cortex (sACC) and the orbitofrontal cortex [3]. However, a recent study using PET revealed that frontal TMS using a double-cone coil can modulate both dorsal and subcallosal ACC as well as a number of more distal cortical areas [9]. Thus this coil can be used in an attempt to suppress alcohol craving as well by potentially targeting the dACC.

We hereby report the temporary abolishment of alcohol craving in an alcohol dependent woman by double cone coil rTMS and demonstrate the associated neurobiological changes with source analyzed EEG and fMRI.

A 48 years old woman, married to a nurse, with one daughter of 10 years old presents at the BRAI²N clinic with a problem of alcohol addiction since her youth, without any other substance abuse, nor major psychiatric comorbidity. The patient initiated treatment on an outpatient basis with one of the authors (GD) in December 2006. At that time she reported having already an extensive history of alcohol dependence problems and at least one prior inpatient treatment episode. Daily, heavy alcohol use started at age 25 and retrospectively first symptoms of dependence were present as from age 35. She has a positive family history of alcoholism (mother and father). The typical drinking pattern is that of binge episodes which can take from several days to several weeks of daily alcohol consumption. These episodes are associated with aggression with amnesia, mood and sleep problems followed by withdrawal symptoms on arresting alcohol intake. This ends with total loss of control and urgent interventions (hospitalization). These periods are followed by longer (getting shorter last years) periods of abstinence of which the longest in the last five years was a period of 6 months. As from 2006 the patient was treated with all currently available medications that have been proven to be effective within the treatment of alcohol dependence. Initially a long-standing period of disulfiram (200 mg daily, under supervision) proved to be effective and resulted in a 6-month abstinence period. However, due to neurological complications (polyneuropathy, type sensitive), this had to be stopped. Following this and in view of the high craving reported by patient and her family, anticraving medication was started. Both acamprosate (initially 2 × 2 and later increased to 3 mg × 2 mg × 333 mg daily) and naltrexone (50 mg/daily) were used for an extensive period of time (longer than 3-months). For both the medications the effect was similar; reduction of craving within the first 6 weeks after initiation followed by a rebound of feelings of craving with subsequent relapse in alcohol-use and loss of control. In addition to the pharmacological treatment extensive psychosocial treatment was offered both on an outpatient and an inpatient basis. These also only yielded a temporary success.

In the months prior to the TMS patient followed a day care (5 days a week) behavioral treatment program focusing on relapse prevention and maintaining abstinence. Weekly, randomized, breathalyzer and urine screening indicated that patient succeeded in maintaining abstinence both from alcohol as illicit drug or benzodiazepine use. However, ultimately patient relapsed in drinking bouts, which continued for two months after the day treatment was ended. During these two months patient was drinking excessively two to three times weekly (as confirmed by collateral information) and was ultimately referred for a TMS trial. Upon starting this trial, patient was in an active drinking period. However, no clinically significant withdrawal symptoms were present, which was in line with the typical drinking pattern of this patient; high levels of

craving, relapse in binge drinking with high BAC but no manifest withdrawal symptoms.

When presenting at the BRAI²N neuromodulation clinic, a sLORETA EEG is performed, to analyze spontaneous electrical brain activity as well as functional connectivity and to rule out epileptic activity, a contraindication for rTMS. An fMRI is performed using images of alcoholic and non-alcoholic beverages as a cue.

The patient underwent three fMRI sessions and three EEG sessions at different time points: (1) before the rTMS session (2) directly after the rTMS session and (3) after relapse. For the fMRI results comparisons were made between the three time points. For EEG a source localized comparison using sLORETA was made between a normative database (the Brain Research Laboratories (BRL), New York University) and respectively before rTMS, directly after rTMS and after relapse. Also a source localized comparison was made between pre and post rTMS. In addition, connectivity analysis was conducted pre and post rTMS. Details on the method can be found in the supplementary materials.

Blood alcohol volume was asked on random days during the stimulation period by using a breathalyzer test (AlcoScan AL-7000). We opted to pick random days, so that patients would not expect this.

TMS is performed using a super rapid stimulator (Magstim Inc, Wales, UK) with a double-cone coil (DDC) (P/N 9902-00; Magstim Co. Ltd) placed over medial frontal cortex (1.5 cm anterior to 1/3 of the distance from the nasion–inion) [4]. The intensity of the stimulation is fixed at 50% machine output in tonic mode. This is done because TMS with the double cone coil at high intensities is very unpleasant for the patient, more so than figure of eight coil stimulation. Furthermore it has been shown that the excitatory measurements of one specific cortex cannot be generalized to the excitability of the whole cortex [10], and TMS motor thresholds cannot be assumed to be a guide to visual [1] and auditory [5] cortex excitability. The patient perceived stimulation at 1 Hz consisting of 600 pulses.

The resting state EEG when the patient scores her craving at 9/10 (but sober, 0‰) is compared to the BRL normative database and demonstrates increased beta (22–23 Hz) activity in the patient in the right ACC and right insula as well as in the left PCC (Fig. 1). There is also bilateral gamma (31–35 Hz) hyperactivity in the patient in comparison to the normative database. Functional connectivity analysis, based on lagged phase synchronization, demonstrates increased synchronized beta and gamma activity in the patient's addicted brain, with the strongest functional beta connection between the PCC and the dACC, the two areas which are hyperactive in comparison to the healthy population (Fig. 2). fMRI, analyzing evoked activity by alcohol cues, demonstrates BOLD activation in almost the same areas as the spontaneous beta activity, suggesting that the hyperactive vmPFC/ACC and PCC are further activated by seeing alcoholic beverages in contrast to non-alcoholic beverages. There is also a BOLD activation of the right nucleus accumbens and left frontal cortex (Fig. 3).

rTMS is initiated at 1 Hz with a double cone coil in an attempt to target the dACC. Daily sessions of 30 min are performed for 3 weeks (Fig. 1S). When initiated the VAS for alcohol craving is 9/10 and Blood alcohol volume of 2.85‰. After 2–6 days of rTMS, this result in a drop of craving to 1/10 and Blood alcohol volume of 0‰ and remains stable during the TMS sessions. The stimulation is continued for 2 more weeks followed by a new EEG and fMRI.

The resting state EEG when the patient scores her craving at 1/10 is compared to the BRL normative database and demonstrates decreased beta (22–23 Hz) activity in the patient in the right ACC at the same location where before rTMS hyperactivity was noted (Fig. 1). The same is noted for the right insula, albeit that the location is minimally more posterior. Gamma band activity is less than in healthy people in the sgACC-nucleus accumbens region. Pre versus

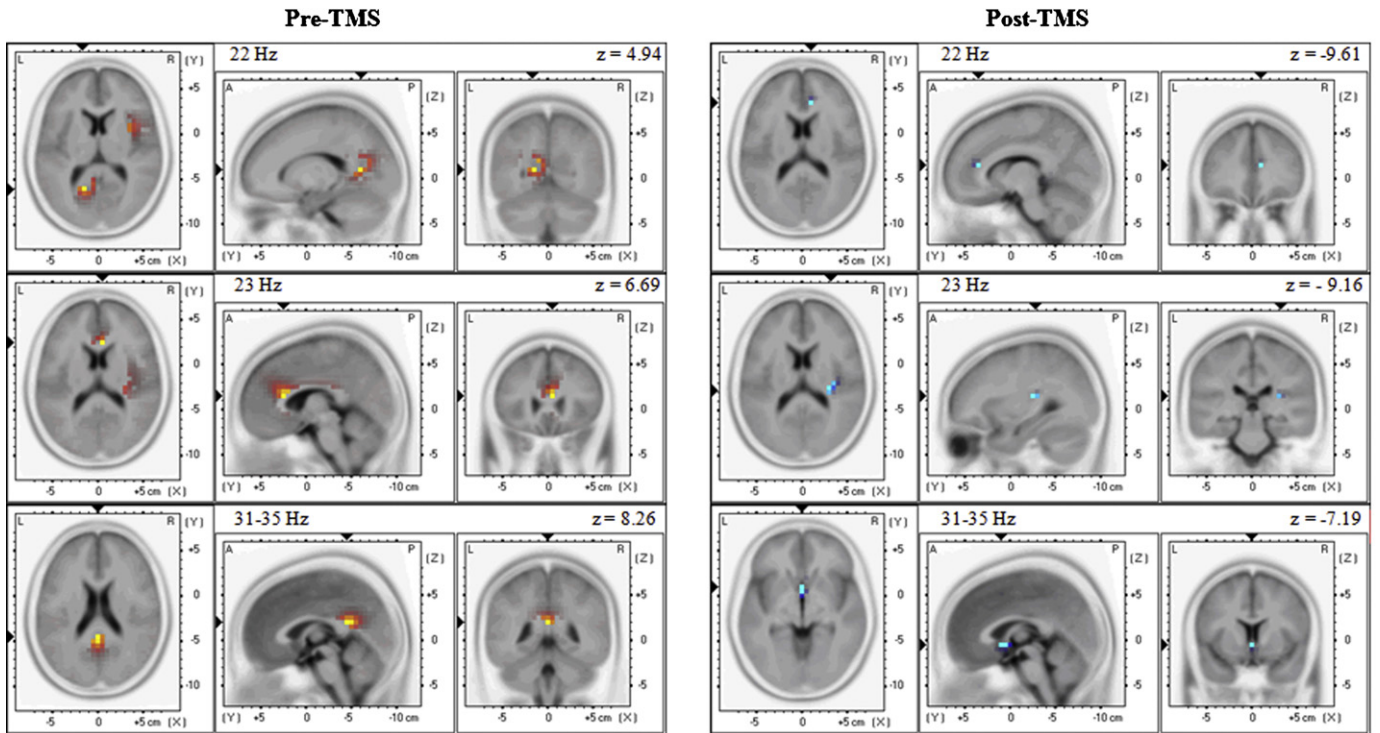


Fig. 1. Resting State EEG comparing patient to a BRL Norm group for respectively 22 Hz (top panel), 23 Hz (central panel) and 31–35 Hz (lower panel) before and after rTMS.

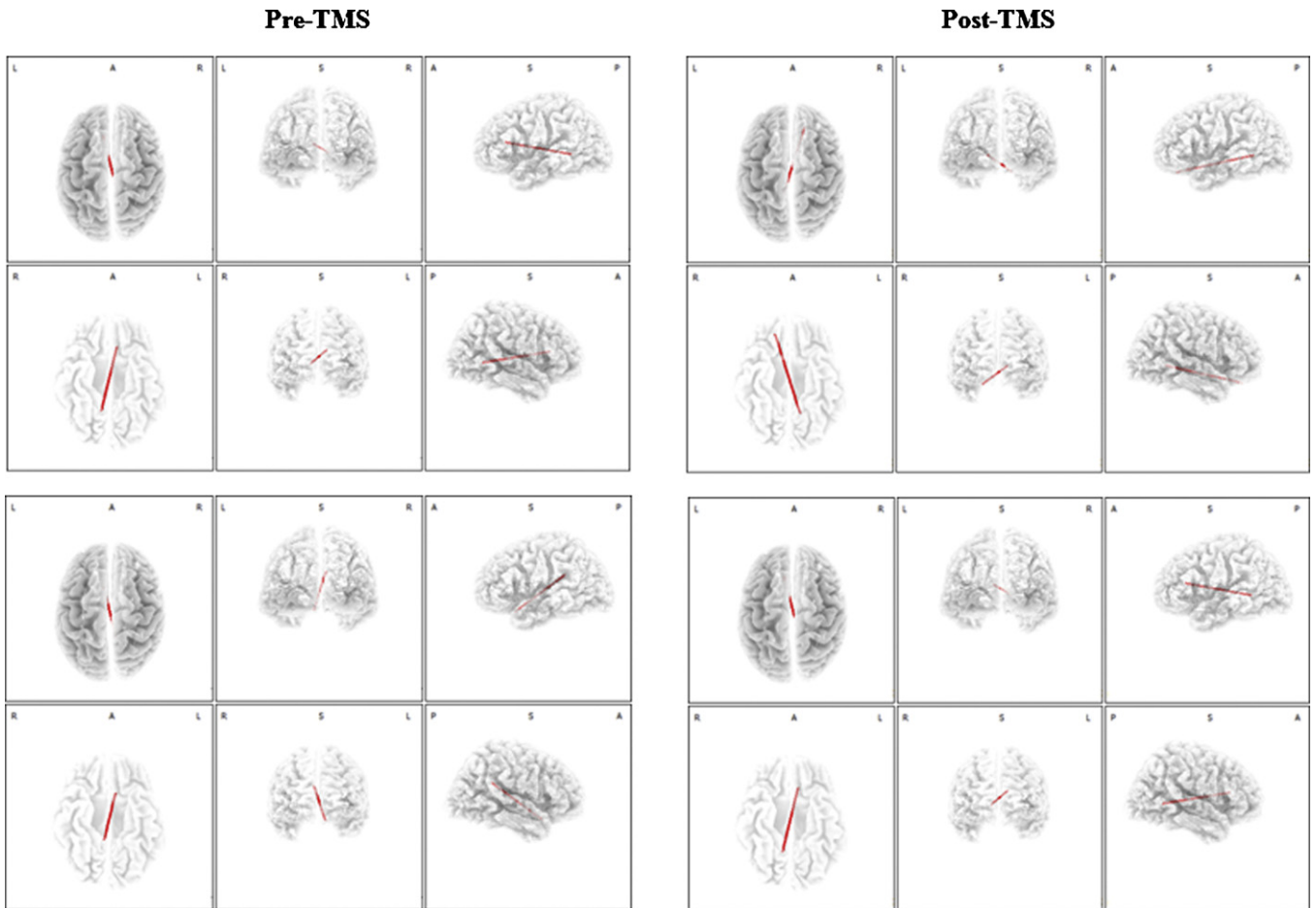


Fig. 2. Functional connectivity for beta (top panels) and gamma (bottom panels) band frequency before (threshold 4.18 and 5.57, respectively) and after (threshold 2.60 and 3.46, respectively) rTMS.

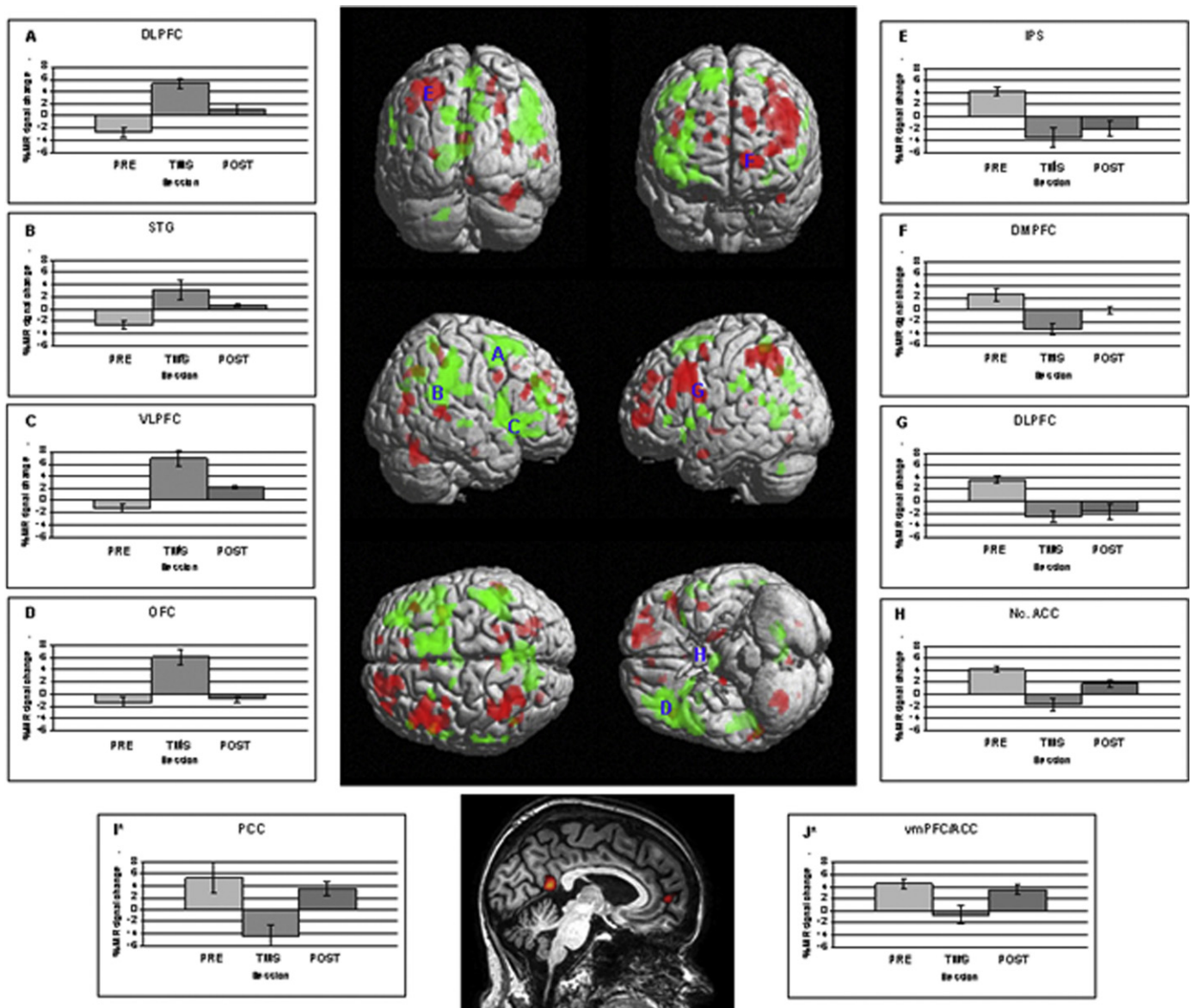


Fig. 3. fMRI activation in different anatomical locations at three time points: (1) before the rTMS session (PRE), (2) directly after the rTMS session (TMS) and (3) after relapse (POST) when comparing picture cues of alcoholic and non-alcoholic beverages (ALC versus BEV). In the middle panel, anatomical locations in which the fMRI activity during ALC was larger than during BEV when comparing session 1 with session 2 are shown in red, overlaid on a 3D rendered anatomical image. Conversely, anatomical locations in which the fMRI activity during ALC was smaller than during BEV when comparing session 1 with session 2 are shown in green, overlaid on a 3D rendered anatomical image. The bargraphs show the fMRI activity (expressed by the mean percent MR signal change) for (A) the right dorsolateral prefrontal cortex (DLPFC), (B) the right superior temporal gyrus (STG), (C) the right ventrolateral prefrontal cortex (VLPFC), (D) the left orbitofrontal cortex (OLF), (E) the left intraparietal sulcus (IPS), (F) the left dorsomedial prefrontal cortex (DMPFC), (G) the left ventrolateral prefrontal cortex (VLPFC), (H) the left nucleus accumbens (Nc. ACC), (I*) the left posterior cingulate cortex (PCC) and (J*) the left anterior cingulate cortex (vmPFC/ACC) in the three sessions. Bars show the mean percent signal change, the error bars the standard deviation. Note that I* and J* are not shown on the 3D rendered anatomical image.

post-TMS on the resting state EEG revealed decreased activity in the beta 1, beta 2 and gamma after TMS demonstrating, respectively decreased activity in the bilateral posterior insula (beta 2), pregenual ACC (beta 3) and anterior (beta 2) and retrosplenial (gamma) PCC (Fig. 3S). Functional connectivity is still increased post TMS for gamma but not for beta, with maximal synchronized activity between the (now suppressed) PCC and the (suppressed) sgACC-nucleus accumbens area (Fig. 2). The fMRI does not demonstrate BOLD activation anymore in the PCC and ACC (Fig. 3) and nucleus accumbens is not activated anymore on fMRI when seeing images of alcohol.

The patient has not developed any signs or symptoms of withdrawal and craving remains suppressed for 3 more months. She can go to a grocery store and walk through the alcohol department

without wanting to buy any bottle, a feat, which she has not been able to do ever. Three months after the rTMS session she reports back to the neuromodulation clinic with a relapsing crave for alcohol. Three months after the rTMS session she reports back to the neuromodulation clinic with a relapsing crave for alcohol (Blood alcohol volume of 1.90‰). One week of rTMS is re-initiated (Blood alcohol volume of 0‰). Three weeks later she relapses again (Blood alcohol volume of 1.45‰) followed by a new rTMS session. Finally she becomes non-responsive to the treatment and is hospitalized again after a binge event with a near lethal dose of alcohol. When the patient relapses there is abnormal gamma band activity, in comparison to the BRL norm group, in overlapping areas: nucleus accumbens-subgenual ACC, pregenual ACC and PCC (Fig. 2S). A post-relapse fMRI (see Fig. 3) demonstrates activity patterns sim-

ilar to the pre-rTMS state for the medial brain structures, i.e. the nucleus accumbens, ACC and PCC, but not for the lateral brain areas.

The most remarkable outcome of this study is the beautiful correlation between the functional imaging data and the clinical picture. When the patient is craving for alcohol, her brain is characterized by beta activity in the ACC and PCC in comparison to non-addicted brains, and these areas are phase synchronized (lagged), meaning co-activated. Normally these areas demonstrate concerted activity as well [14], but in this patient the functional connectivity between these two parts of the cingulate cortex is markedly increased for beta activity. However an anatomical connectivity study demonstrates that the superior cingulum bundle is degenerated in people with alcohol dependency [16]. This seemingly contradictory finding could hypothetically be explained by chronic hyperactivity related excitotoxic degeneration. The fMRI findings almost perfectly match the resting state (craving) activity of the brain: evoking an even stronger craving by presenting images of alcoholic beverages (in contrast to non-alcoholic beverages) activates the same areas that are already hyperactive in comparison to a non-alcoholic population even more.

The activity and functional connectivity changes might be causally related to the craving, as these neural correlates change after rTMS when craving is absent. The same anterior cingulate and insular areas that were hyperactive during craving are less active in the same frequencies in comparison to a non-addictive population post-rTMS, when craving almost absent. But the sgACC-nucleus accumbens area demonstrates less gamma activity than a normal population as well, suggesting that the double cone rTMS does influence the reward system. This nucleus accumbens and sgACC change is confirmed by the fMRI data, which yield a much better spatial resolution. This sgACC suppression is in accordance with the PET study performed during rTMS with a similar coil targeting the same region [9]. The functional connectivity changes accordingly, and the strongest connectivity changes from PCC–dACC to PCC–sgACC. Hypothetically the most dominant information transmission at rest seems to switch from the degenerated superior to the non-degenerated inferior cingulum bundle. Based on functional connectivity data obtained by resting state fMRI this correlated activity between the PCC and the sgACC is normal as well [14]. Post TMS it is interesting that the dominant phase synchronization occurs between the normalized PCC and the hypofunctioning sgACC-nucleus accumbens region. Functional MRI demonstrates that the images of alcoholic beverages do not evoke activation of the PCC and accumbens-sgACC anymore but more widespread activation. It would be of interest to see whether this activation pattern is similar in a non-addicted population. However at this stage it is impossible to state with certainty whether the changes in brain activity and brain connectivity are related to the rTMS, the decrease in alcohol intake or the decrease in craving. Studying a larger group of patients and performing correlation analyses might help to solve this conundrum, as might be path modeling studies on larger groups of patients.

The patient finally relapsed even though she had continued rTMS sessions. Two possible explanations can be proposed for this. The first is that the treatment was placebo, as it is known that craving is placebo-sensitive. Even though placebo cannot be ruled out as the mechanism that caused the transient improvement, it is unlikely that the sham effect took 2–4 days to develop, with a different time course for morning, midday and evening craving, without developing any withdrawal symptoms and that it lasted for a couple of months (Fig. 1S). It is more likely that the patient habituated to the stimulation, an effect well known in electrical stimulation [4]. In addition, it might be that the rTMS effect is a non-specific effect, in view of the fact that the patient had a transient craving reduction with every treatment that had been tried in the past. A second explanation could be that whereas the applied

stimulation was adapted to the brain state at the beginning of the treatment, the same stimulation was not adapted for the brain state after the rTMS sessions. It is well known that TMS effects are brain state dependent [2,19], and the brain state at relapse is different than before rTMS was initiated even though the clinical picture is similar, i.e. high craving. A further argument for this hypothesis can be derived from the fact that the lateral brain areas are differentially activated post-relapse even though the clinical picture is similar. Therefore applying the same stimulation pattern targeting the same area might not be warranted. A more dynamical adaptive stimulation design might be required to solve this problem.

A pathophysiological approach is described to suppress alcohol craving by rTMS directed at the anterior cingulate. Linking functional imaging changes to craving intensity suggests this approach warrants further exploration.

Appendix A. Supplementary data

Supplementary data associated with this article can be found, in the online version, at doi:10.1016/j.neulet.2011.03.074.

References

- [1] R. Amiaz, D. Levy, D. Vainiger, L. Grunhaus, A. Zangen, Repeated high-frequency transcranial magnetic stimulation over the dorsolateral prefrontal cortex reduces cigarette craving and consumption, *Addiction* 104 (2009) 653–660.
- [2] Z. Cattaneo, F. Rota, T. Vecchi, J. Silvano, Using state-dependency of transcranial magnetic stimulation (TMS) to investigate letter selectivity in the left posterior parietal cortex: a comparison of TMS-priming and TMS-adaptation paradigms, *Eur. J. Neurosci.* 28 (2008) 1924–1929.
- [3] S.S. Cho, A.P. Strafella, rTMS of the left dorsolateral prefrontal cortex modulates dopamine release in the ipsilateral anterior cingulate cortex and orbitofrontal cortex, *PLoS ONE* 4 (2009) e6725.
- [4] D. De Ridder, G. De Mulder, T. Menovsky, S. Snaert, S. Kovacs, Electrical stimulation of auditory and somatosensory cortices for treatment of tinnitus and pain, *Prog. Brain Res.* 166 (2007) 377–388.
- [5] L. Degenhardt, W.T. Chiu, N. Sampson, R.C. Kessler, J.C. Anthony, M. Angermeyer, R. Bruffaerts, G. de Girolamo, O. Gureje, Y. Huang, A. Karam, S. Kostyuchenko, J.P. Lepine, M.E. Mora, Y. Neumark, J.H. Ormel, A. Pinto-Meza, J. Posada-Villa, D.J. Stein, T. Takeshima, J.E. Wells, Toward a global view of alcohol, tobacco, cannabis, and cocaine use: findings from the WHO World Mental Health Surveys, *PLoS Med.* 5 (2008) e141.
- [6] P. Eichhammer, M. Johann, A. Kharraz, H. Binder, D. Pittrow, N. Wodarz, G. Hajak, High-frequency repetitive transcranial magnetic stimulation decreases cigarette smoking, *J. Clin. Psychiatry* 64 (2003) 951–953.
- [7] A. Erhardt, I. Sillaber, T. Welt, M.B. Muller, N. Singewald, M.E. Keck, Repetitive transcranial magnetic stimulation increases the release of dopamine in the nucleus accumbens shell of morphine-sensitized rats during abstinence, *Neuropsychopharmacology* 29 (2004) 2074–2080.
- [8] B.F. Grant, D.A. Dawson, F.S. Stinson, S.P. Chou, M.C. Dufour, R.P. Pickering, The 12-month prevalence and trends in DSM-IV alcohol abuse and dependence: United States, 1991–1992 and 2001–2002, *Drug Alcohol Depend.* 74 (2004) 223–234.
- [9] G. Hayward, M.A. Mehta, C. Harmer, T.J. Spinks, P.M. Grasby, G.M. Goodwin, Exploring the physiological effects of double-cone coil TMS over the medial frontal cortex on the anterior cingulate cortex: an H2(15)O PET study, *Eur. J. Neurosci.* 25 (2007) 2224–2233.
- [10] J.H. Ko, O. Monchi, A. Pfitz, P. Bloomfield, S. Houle, A.P. Strafella, Theta burst stimulation-induced inhibition of dorsolateral prefrontal cortex reveals hemispheric asymmetry in striatal dopamine release during a set-shifting task: a TMS-(11C)raclopride PET study, *Eur. J. Neurosci.* 28 (2008) 2147–2155.
- [11] G.F. Koob, M. Le Moal, Addiction and the brain antireward system, *Annu. Rev. Psychol.* 59 (2008) 29–53.
- [12] A.R. Lingford-Hughes, M.R. Dalglis, B.J. Stevenson, A. Feeney, S.A. Pandit, S.J. Wilson, J. Myles, P.M. Grasby, D.J. Nutt, Imaging alcohol cue exposure in alcohol dependence using a PET 15O-H2O paradigm: results from a pilot study, *Addict. Biol.* 11 (2006) 107–115.
- [13] E.D. London, S.M. Berman, P. Mohammadian, T. Ritchie, M.A. Mandelkern, M.K. Susselman, F. Schlagenhaut, E.P. Noble, Effect of the TaqIA polymorphism on ethanol response in the brain, *Psychiatry Res.* 174 (2009) 163–170.
- [14] D.S. Margulies, A.M. Kelly, L.Q. Uddin, B.B. Biswal, F.X. Castellanos, M.P. Milham, Mapping the functional connectivity of anterior cingulate cortex, *Neuroimage* 37 (2007) 579–588.
- [15] B.R. Mishra, S.H. Nizamie, B. Das, S.K. Praharaj, Efficacy of repetitive transcranial magnetic stimulation in alcohol dependence: a sham-controlled study, *Addiction* 105 (2010) 49–55.

- [16] A. Pfefferbaum, M. Rosenbloom, T. Rohlfing, E.V. Sullivan, Degradation of association and projection white matter systems in alcoholism detected with quantitative fiber tracking, *Biol. Psychiatry* 65 (2009) 680–690.
- [17] E. Politi, E. Fauci, A. Santoro, E. Smeraldi, Daily sessions of transcranial magnetic stimulation to the left prefrontal cortex gradually reduce cocaine craving, *Am. J. Addict.* 17 (2008) 345–346.
- [18] M.C. Ridding, J.C. Rothwell, Is there a future for therapeutic use of transcranial magnetic stimulation? *Nat. Rev. Neurosci.* 8 (2007) 559–567.
- [19] J. Silvanto, N. Muggleton, V. Walsh, State-dependency in brain stimulation studies of perception and cognition, *Trends Cogn. Sci.* 12 (2008) 447–454.
- [20] R. Sinha, C.S. Li, Imaging stress- and cue-induced drug and alcohol craving: association with relapse and clinical implications, *Drug Alcohol Rev.* 26 (2007) 25–31.
- [21] S.F. Tapert, G.G. Brown, M.V. Baratta, S.A. Brown, fMRI BOLD response to alcohol stimuli in alcohol dependent young women, *Addict. Behav.* 29 (2004) 33–50.