

Structural correlates of the audiological and emotional components of chronic tinnitus

Shaheen Ahmed^a, Anusha Mohan^b, Hye Bin Yoo^a, Wing Ting To^c, Silvia Kovacs^b, Stefan Sunaert^b, Dirk De Ridder^c, and Sven Vanneste^{a,b,*}

^a*Lab for Integrative & Clinical Neuroscience, School of Behavioral and Brain Sciences, The University of Texas at Dallas, Richardson, TX, United States*

^b*Global Brain Health Institute & Institute of Neuroscience, Trinity College Dublin, Dublin, Ireland*

^c*School of Nursing & Midwifery, Trinity College Dublin, Dublin, Ireland*

**Corresponding author: Tel.: +353-8-772-11893, e-mail address: sven.vanneste@tcd.ie*

Abstract

The objective is to investigate white matter tracts, more specifically the arcuate fasciculus and acoustic radiation, in tinnitus and assess their relationship with distress, loudness and hearing loss. DTI images were acquired for 58 tinnitus patients and 65 control subjects. Deterministic tractography was first performed to visualize the arcuate fasciculus and acoustic radiation tracts bilaterally and to calculate tract density, fractional anisotropy, radial diffusivity, and axial diffusivity for tinnitus and control subjects. Tinnitus patients had a significantly reduced tract density compared to controls in both tracts of interest. They also exhibited increased axial diffusivity in the left acoustic radiation, as well as increased radial diffusivity in the left arcuate fasciculus, and both the left and right acoustic radiation. Furthermore, they exhibited decreased fractional anisotropy in the left arcuate fasciculus, as well as the left and right acoustic radiation tracts. Partial correlation analysis showed: (1) a negative correlation between arcuate fasciculus tract density and tinnitus distress, (2) a negative correlation between acoustic radiation tract density and hearing loss, (3) a negative correlation between acoustic radiation tract density and loudness, (4) a positive correlation between left arcuate fasciculus and tinnitus distress for radial diffusivity, (5) a negative correlation between left arcuate fasciculus and tinnitus distress for fractional anisotropy, (6) a positive correlation between left and right acoustic radiation and hearing loss for radial diffusivity, (7) No correlation between any of the white matter characteristics and tinnitus loudness. Structural alterations in the acoustic radiation and arcuate fasciculus correlate with hearing loss and distress in tinnitus but not tinnitus loudness showing that loudness is a more functional correlate of the disorder which does not manifest structurally.

Keywords

Diffusion tensor imaging, Demyelination, Axonal degeneration, Distress, Hearing loss, Tinnitus, DTI

Abbreviations

AD	axial diffusivity
BET	brain extraction tool
DTI	diffusion tensor imaging
EEG	electroencephalography
EPI	echo planar imaging
FA	fractional anisotropy
fMRI	functional magnetic resonance imaging
FOV	field of view
MEG	magnetoencephalography
MBP	myelin basic protein
RD	radial diffusivity
SE	single-shot spin echo
TFE	turbo field echo
TQ	tinnitus questionnaire

1 Introduction

Tinnitus is an auditory phantom percept characterized by a hissing, tonal, or buzzing sound in the absence of a physical sound source (Jastreboff, 1990). The American Tinnitus Association estimates that 50 million Americans perceive tinnitus. 6%–25% of affected people are severely debilitated, with 2%–4% suffering severely enough to seek medical attention (Axelsson and Ringdahl, 1989). Clinical tinnitus assessment usually involves measurements of tinnitus loudness (sensory component), tinnitus distress, as well as evaluation of mood (emotional component) (Langguth et al., 2013) and hearing loss which is most commonly present in tinnitus patients (Axelsson and Sandh, 1985; Huang and Tang, 2010). Several studies have consensually agreed on the functional changes in the brain in the presence of tinnitus using EEG, fMRI and MEG and their relevance with tinnitus components and the amount of hearing loss (Lau et al., 2018; Maudoux et al., 2012; Van Der Loo et al., 2009; Vanneste et al., 2010). However, previous research that have examined structural changes in white matter using Diffusor Tensor Imaging (DTI) in tinnitus patients have arrived at contradictory results (Benson et al., 2014). The absence of consensual evidence neural correlates of changes in white matter integrity and tinnitus symptoms may be attributed to the highly multicollinear nature of the behavioral

variables associated with tinnitus. Therefore, the two main aims of the current study are (a) to investigate structural changes in white matter integrity in tinnitus patients compared to a control group and (b) to assess the precise behavioral relevance of these changes by controlling for the potential confounding variables.

DTI is a sensitive and noninvasive tool for assessing white matter tract integrity in the central nervous system, based on the diffusive properties of water molecules (Basser et al., 1994; Neil et al., 2002). Diffusion of water molecules in the white matter of the brain is hindered by several characteristics such as the structural arrangement of axons, axon membranes, neurofilaments, and the myelin coating around the neurons (Beaulieu, 2002). The directionality of water movement in the presence of barriers is known as *fractional anisotropy* (FA). The overall magnitude of water movement is quantified as mean diffusivity. The magnitude of water movement along the axon and perpendicular to the axon are defined as *axial diffusivity* (AD) and *radial diffusivity* (RD), respectively. AD is related to the intrinsic characteristics of the axons or changes in the extra-axonal/extracellular space (Papadakis et al., 1999; Pierpaoli and Basser, 1996; van Pul et al., 2005; Wang et al., 2006), while RD is a surrogate of changes associated with myelination (Song et al., 2002).

These measures (FA, AD and RD) characterizing the various properties of white matter tract integrity has shown to be a promising avenue of investigation for tinnitus in particularly two white matter tracts—arcuate fasciculus and acoustic radiation. The first tract, the arcuate fasciculus, is an association tract connecting the auditory cortex with frontal and parietal cortices (Catani and Mesulam, 2008). It has been associated with cognitive expression of patients' mood (Pujol et al., 2000) and structural changes have been identified in several psychiatric disorders such as autism spectrum disorders, schizophrenia, dyslexia and dyscalculia (Salviati et al., 2014). The second tract, the acoustic radiation, conveys auditory information from the medial geniculate body of the thalamus to the auditory cortex (Maffei et al., 2018). More specifically the medial geniculate body is known as the auditory thalamus which acts as an inhibitory mechanism that suppresses the tinnitus percept (loudness) in subjects with hearing loss (Richardson et al., 2012).

A first DTI study investigated the integrity of white matter in the arcuate fasciculus. The authors found a reduction in FA, reflecting underlying dysfunction of the associated fibers in tinnitus patients. These findings were replicated and extended, identifying reduced FA in right prefrontal areas, left inferior and superior longitudinal fasciculus, and anterior thalamic radiation (Aldhafeeri et al., 2012). Contradicting these findings, however, increased FA was found in similar areas, including the inferior longitudinal fasciculus and anterior thalamic radiation (Benson et al., 2014), and in auditory and limbic areas in tinnitus compared to controls (Crippa et al., 2010). Several other studies, reported a positive correlation between loudness and FA and a negative correlation between loudness and RD as well as AD in both the anterior thalamic radiation and ventromedial prefrontal cortex (Leaver et al., 2012; Seydell-Greenwald et al., 2014).

Furthermore, Lin and colleagues found an increase in RD, suggesting the presence of demyelination at the level of the lateral lemniscus and inferior colliculus (Lin et al., 2008). They also found that hearing loss, but not tinnitus, was associated with white matter alterations (Lin et al., 2008). Another study noted an increase in AD in left superior, middle, and inferior temporal white matter (parts of the acoustic radiation), suggesting axonal degeneration in tinnitus patients in comparison to control subjects (Ryu et al., 2016). More recent studies further suggested that differences in white matter between tinnitus patients and controls could be explained by age and hearing thresholds rather than tinnitus characteristics (Yoo et al., 2016).

In this way, the literature covering white matter changes in tinnitus leads to confusing and contradictory conclusions. The reported variability in white matter integrity could be explained by the anatomical heterogeneity of the tinnitus sample in these studies (Schmidt et al., 1679). More specifically, factors such as age, distress, and hearing loss could drive the anatomical differences reported across studies. Therefore, our first aim of the current study is to clarify the changes in structural characteristics of these two axonal bundles (arcuate fasciculus and acoustic radiation) in tinnitus by investigating their white matter integrity (FA), axonal degeneration (AD) and axonal demyelination (RD) using DTI. The second aim of the current study is to associate structural changes in these two tracts to the emotional and sensory components of tinnitus and the amount of hearing loss, presenting the structural correlates of tinnitus symptoms after controlling for other multicollinear factors. Since the arcuate fasciculus connects frontal with temporal and parietal regions, we hypothesize a strong relationship between its different white matter characteristics and tinnitus related distress. Similarly, since the acoustic radiation connects more auditory areas and shown to be affected by age and hearing loss, we hypothesize a strong relationship between its different white matter characteristics and tinnitus loudness and hearing loss.

2 Methods and materials

2.1 Participants

The study included 58 tinnitus patients (34 males, 24 females) aged 20–74 years (52.66 ± 11.66) and 65 healthy subjects (38 males, 27 females) aged 27–66 years (49.28 ± 8.74). Tinnitus patients having a history of chronic headache, neurological disorders such as brain tumors, traumatic brain injury, and/or being treated for mental disorders were excluded from the study. All healthy subjects had a negative history of psychiatric and neurologic disorders and were enrolled in the study after completion of an informed consent. See Table 1 for a summary of demographic information and related data in each group. All patients agreed to make no changes to their current

Table 1 Demographic of the participants in control and tinnitus group.

Demographics	Controls	Tinnitus
Number of participants	65	58
Age	(49.28 ± 8.74) years	(52.66 ± 11.66) years
Sex	38 Male, 27 Female	34 Male, 24 Female
Mean hearing loss	Not recorded	26.02 ± 12.48
Tinnitus type		Tonal = 31; Noise = 26
Tinnitus loudness (NRS)		5.8 ± 2.198
Tinnitus distress (TQ)		50 ± 20.8

medication intake, which primarily included the aforementioned medications. All patients gave written informed consent, and the ethical committee approved the study.

All patients were interviewed regarding the tinnitus location (left ear, right ear, in both ears), tinnitus duration, as well as the tinnitus sound characteristics (pure tone-like or noise-like tinnitus). There were 31 patients who perceived a pure tone-like tinnitus (17 males and 14 females; 16 with left-sided and 15 with right-sided tinnitus) and 26 patients who perceived a noise-like tinnitus (16 males and 10 females; 14 with left-sided and 12 with right-sided tinnitus). Additionally, the patients were tested for hearing loss using pure tone audiometry inside the scanner before the MRI session using a homebuilt Presentation[®] (Neurobehavioral Systems, Albany, CA, USA) script. The pure tone hearing threshold was determined for eight different frequencies (0.125, 0.250, 0.5, 1, 2, 4, 6, 8 kHz) presented unilaterally and randomly via a stepwise procedure (Ulmer et al., 1998). At the start of the cycle of operations, a pure tone was presented at a specific loudness which is increased in a stepwise manner until audible. Patients were instructed to press a response button when a tone was heard. Based on this audiogram, the hearing loss was calculated by averaging the hearing thresholds over all frequencies measured. Furthermore, a pitch scaling experiment was conducted to determine the frequency of the tinnitus percept for each patient inside the scanner using an MRI-compatible headphone system. During the experiment, patients were asked to determine whether the binaurally presented pure tones or bandpass noises were lower than, higher than, or equal to the pitch of their tinnitus. Fig. 1 shows the mean audiogram for the tinnitus patients.

A numeric rating scale (NRS) for tinnitus loudness and Tinnitus Questionnaire (TQ) for tinnitus related distress were collected for all patients. The NRS ranged from 0 to 10 (“How loud is your tinnitus?”: 0=no tinnitus and 10=the worst possible tinnitus). The TQ measures emotional and cognitive distress, intrusiveness, auditory perceptual difficulties, sleep disturbances, and somatic complaints. Based on the total TQ score (0–84), patients were assigned to a distress category: slight (0–30: grade 1), moderate (31–46: grade 2), severe (47–59: grade 3) and very severe (60–84, grade 4).

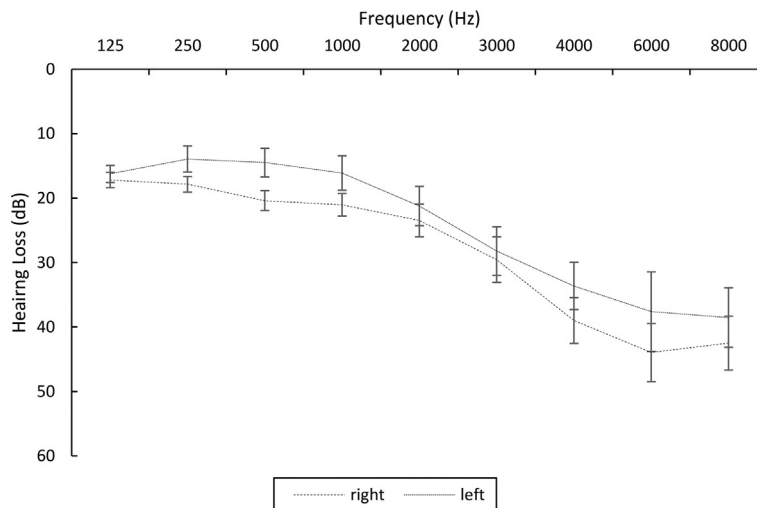


FIG. 1

Audiogram.

2.2 Data acquisition and processing

DTI data sets were obtained on a 3T MR scanner (INTERA, Philips Medical Systems, Best, The Netherlands) with an eight-channel phased-array head coil using a single-shot spin echo (SE) echo planar imaging (EPI) sequence with the following acquisition parameters: 68 contiguous sagittal slices; 112×109 acquisition matrix; field of view (FOV) = $220 \times 220 \text{ mm}^2$; TR = 15.0 min; TE = 48 ms; 2.5 parallel imaging factor (AP direction); b-value = 800 s/mm^2 ; acquisition time = 9 min 59 s. Diffusion measurements were performed along 32 directions with additionally one non-diffusion weighted (b_0) image.

For anatomical reference, an additional high-resolution 3D T1-weighted turbo field echo (TFE) sequence was used with a TE/TR of 4.60/9.60 ms and an acquired voxel size of $0.98 \times 0.98 \times 1.20 \text{ mm}^3$ (acquisition matrix $256 \times 256 \text{ mm}^2$, FOV $250 \times 250 \text{ mm}^2$). Parallel imaging factors of 1.5 in RL direction and 2 in AP direction were used. A coronal stack of 182 contiguous slices was acquired resulting in a total scan time of 6 min 23 s. No contrast agent was administered.

The diffusion weighted datasets were visually inspected for excessive motion and artifacts. Based on this inspection, single bad images were removed from seven participants (four control and three tinnitus patients). Following quality inspection, FSL “eddy current” function was performed to align all images acquired for single subject to the first non-diffusion weighted image (b_0) of that subject using 12-parameter affine transformation. This function corrects for motion between successive images as well as for distortions caused by eddy currents, which differ for images acquired with diffusion weighting in different directions. To obtain a mask for limiting further analysis steps to voxels inside the brain FSL’s brain extraction

tool “BET” was used on the first b0 image of each subject. Parameters were adjusted and manual corrections were made as needed to ensure the resulting mask does not include the surrounding skull tissues.

Following the preprocessing, a diffusion tensor was estimated for each voxel in each subject-concatenated dataset using FSL “DTIfit” function. Apart from the 4D dataset and the mask file, the function also calls for gradient vector (bvec) and gradient value (bval) text files. “bvec” files describe the gradient directions with which each of the images in the 4D dataset were acquired and “bval” describing the diffusion weighting applied when acquiring images for $b=0\text{ s/mm}^2$ and $b=800\text{ s/mm}^2$. After tensor fitting, FA, AD (eigenvalue λ_1), and RD (average of λ_2, λ_3) maps were obtained. All the maps were inspected for artifacts separately for each subject. FA is a measure of white matter integrity, expressed in the ratio ranging from 0 to 1 (0 = isotropic or no predilection for any particular direction and 1 = anisotropic or unidirectional), where a higher score reflects more normal white matter. AD measures the rate of diffusion in the longitudinal direction of the axon and RD measures the rate of diffusion in the transverse direction (Chanraud et al., 2010; Pierpaoli and Basser, 1996; Vilanova et al., 2006).

The diffusion-weighted images for all subjects were registered to the FSL standard template with a resolution of $1 \times 1 \times 1\text{ mm}^3$. All the registered diffusion weighted images were concatenated, and the gradient vectors were also combined so that they can be processed as a super dataset. The tensor fit was obtained for the super dataset resulting in group fractional anisotropy image. The tractography was performed using Fiber Track software installed in Philips scanner to map the white matter tracts for arcuate fasciculus and acoustic radiation. For quantitative analysis, tract density was computed as

$$Density = \frac{\text{Number of tracts passing the region of interest}}{\text{Total number of tracts in the brain}}.$$

2.3 Statistical analysis

2.3.1 Significant tracts for FA, AD, and RD

Multivariate ANOVA was performed comparing tract density, FA, AD, and RD between controls and tinnitus for the left arcuate fasciculus, right arcuate fasciculus, left acoustic radiation, and right acoustic radiation. For those measures with a significant group \times tract interaction determined at $P < 0.05$, a univariate ANOVA was performed to disentangle the group level difference between these measures for each tract.

3 Partial correlation between tracts and behavioral measures

Partial correlation analyses were performed between tract density, FA, AD, and RD of the four tracts and the behavioral measures. The tract density of the four tracts were partially correlated with distress (controlling for hearing loss and loudness),

hearing loss (controlling for distress and loudness) and loudness (controlling for hearing loss and distress). These correlations were corrected for multiple comparisons for the number of tracts (4) * the number of correlation measures (3) at $P < 0.004$ using Bonferroni correction.

The three measures of white matter integrity for the bilateral arcuate fasciculus were partially correlated with distress (controlling for hearing loss and loudness), hearing loss (controlling for distress and loudness) and loudness (controlling for hearing loss and distress). Since the three measures of white matter integrity are considered independent of one another, the correlations were correct for multiple comparisons for the number of tracts (2) * number of correlation measures (3) at $P < 0.008$ using Bonferroni correction.

The three measures of white matter integrity for the bilateral acoustic radiation were partially correlated with hearing loss (controlling for age and loudness), loudness (controlling for hearing loss and age) and age (controlling for hearing loss and loudness) since they have been shown to be affected by measures of age and hearing loss. Since the three measures of white matter integrity are considered independent of one another, the correlations were correct for multiple comparisons for the number of tracts (2) * number of correlation measures (3) at $P < 0.008$ using Bonferroni correction.

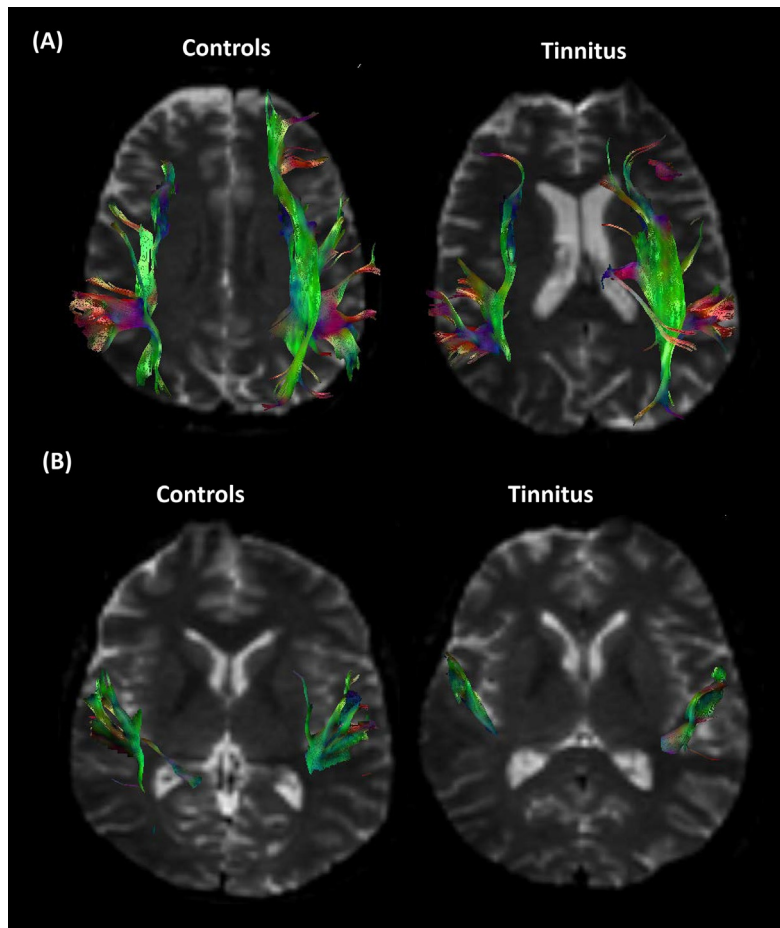
4 Results

4.1 Tract density

Fig. 2A shows the tractography of the arcuate fasciculus in the control and tinnitus group. We observe that the tinnitus group shows thinning and missing tracts for frontal, parietal, and temporal regions. Fig. 2B shows the tractography of the acoustic radiation in the control and tinnitus group. The tinnitus group shows missing tracts for the temporal region. The tract density difference for the tinnitus vs control group was found to be statistically significant ($F = 20.24$, $P = 0.01$). The tinnitus group has a significantly reduced tract density compared to the control group for left arcuate fasciculus ($F = 6.34$, $P = 0.013$), right arcuate fasciculus ($F = 6.35$, $P = 0.012$), left acoustic radiation ($F = 4.42$, $P = 0.038$), and right acoustic radiation ($F = 6.83$, $P = 0.01$), shown in Fig. 3A.

4.2 Significant tracts for FA, AD, and RD

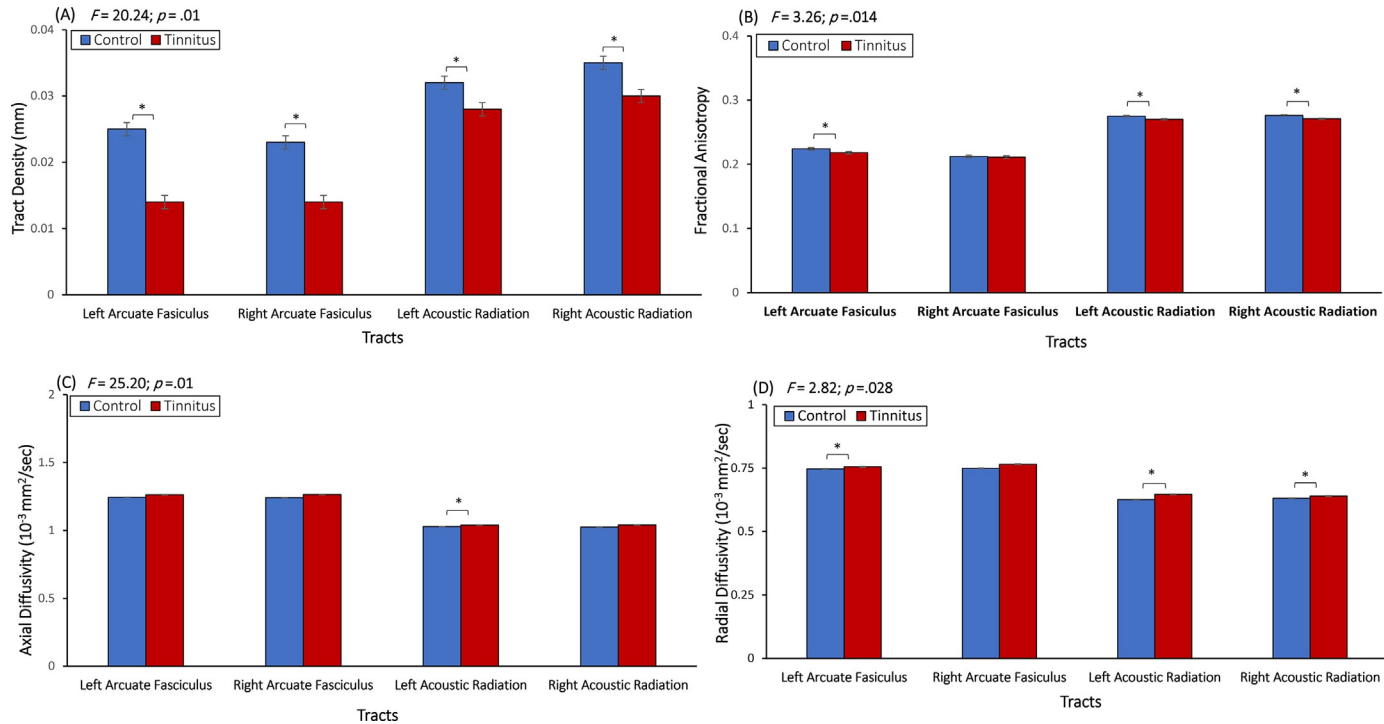
For FA, the difference between the tinnitus vs control group was statistically significant ($F = 3.26$, $P = 0.014$). The tinnitus group has significantly decreased anisotropy compared to the control group for left arcuate fasciculus ($F = 5.87$, $P = 0.017$), left acoustic radiation ($F = 5.39$, $P = 0.022$), and right acoustic radiation ($F = 6.51$, $P = 0.012$). No significant decrease in anisotropy was observed for the right arcuate fasciculus ($F = 0.25$, $P = 0.62$), shown in Fig. 3B.

**FIG. 2**

(A) Tractography for arcuate fasciculus in control and tinnitus group; (B) Tractography for acoustic radiation in control and tinnitus group.

For AD, the difference between the tinnitus vs control group was statistically significant ($F=25.20$, $P=0.01$). The tinnitus group has significantly increased AD compared to control group for left acoustic radiation ($F=3.63$, $P=0.041$). No significant increase for AD was observed for left arcuate fasciculus ($F=2.15$, $P=0.154$), right arcuate fasciculus ($F=2.15$, $P=0.15$), or right acoustic radiation ($F=2.73$, $P=0.055$), shown in Fig. 3C.

For RD, the difference between the tinnitus vs control group was statistically significant ($F=2.82$, $P=0.028$). The tinnitus group has significantly increased RD compared to the control group for left arcuate fasciculus ($F=4.39$, $P=0.038$), left

**FIG. 3**

(A) A comparison between control vs tinnitus group for the tract density for the left and right arcuate fasciculus and the left and right acoustic radiation; (B) A comparison between control vs tinnitus group for fractional anisotropy for the left and right arcuate fasciculus and the left and right acoustic radiation; (C) A comparison between control vs tinnitus group for axial diffusivity for the left and right arcuate fasciculus and the left and right acoustic radiation; (D) A comparison between control vs tinnitus group for radial diffusivity for the left and right arcuate fasciculus and the left and right acoustic radiation.

acoustic radiation ($F=4.71$, $P=0.032$), and right acoustic radiation ($F=5.68$, $P=0.019$). No significant increase was observed for the right arcuate fasciculus ($F=1.48$, $P=0.23$), shown in Fig. 3D.

4.3 Partial correlation analysis

4.3.1 Arcuate fasciculus

With respect to tract density, significant partial correlations were observed for the left arcuate fasciculus and distress ($r=-0.40$, $P=0.002$) and for the right arcuate fasciculus and distress ($r=-0.40$, $P=0.002$), both controlling for hearing loss and loudness, as shown in Fig. 4A–B. No significant partial correlations were observed for the left arcuate fasciculus and hearing loss or for the right arcuate fasciculus and hearing loss when controlling for loudness and distress. No significant partial correlations were observed for the left arcuate fasciculus and loudness or for the right arcuate fasciculus and loudness when controlling for hearing loss and distress. See Table 2 for an overview.

With respect to FA, a significant partial correlation was observed for the left arcuate fasciculus and distress, controlling for hearing loss and loudness ($r=-0.50$, $P=0.003$). No significant correlation was observed for the right arcuate fasciculus. For AD, no significant partial correlation was observed for the left arcuate fasciculus and distress or for the right arcuate fasciculus and distress when controlling for hearing loss and loudness. For RD, a significant partial correlation was observed for the left arcuate fasciculus and distress, controlling for hearing loss and loudness ($r=0.39$, $P=0.002$). No significant correlation was observed for the right arcuate fasciculus. See Table 3 for an overview.

For hearing loss, no significant partial correlation was observed between the left and the right arcuate fasciculus after controlling for distress and loudness when looking at RD, FA, or AD. In addition, when looking at RD, FA, and AD, no significant partial correlation was observed between left and right arcuate fasciculus and loudness when controlling for hearing loss and distress.

5 Acoustic radiation

With respect to tract density, no significant partial correlation was observed between the left ($r=0.04$, $P=0.79$) nor right ($r=0.04$, $P=0.79$) acoustic radiation and distress after controlling for hearing loss and loudness. Significant correlation was observed between the left acoustic radiation and hearing loss ($r=-0.34$, $P=0.002$), and between the right acoustic radiation and hearing loss ($r=-0.34$, $P=0.002$) after controlling for loudness and distress. No significant correlation was observed between left acoustic radiation ($r=-0.18$, $P=0.21$), nor right ($r=-0.13$, $P=0.38$) acoustic radiation and loudness after controlling for hearing loss and distress. See Fig. 3C–D and Table 2 for an overview.

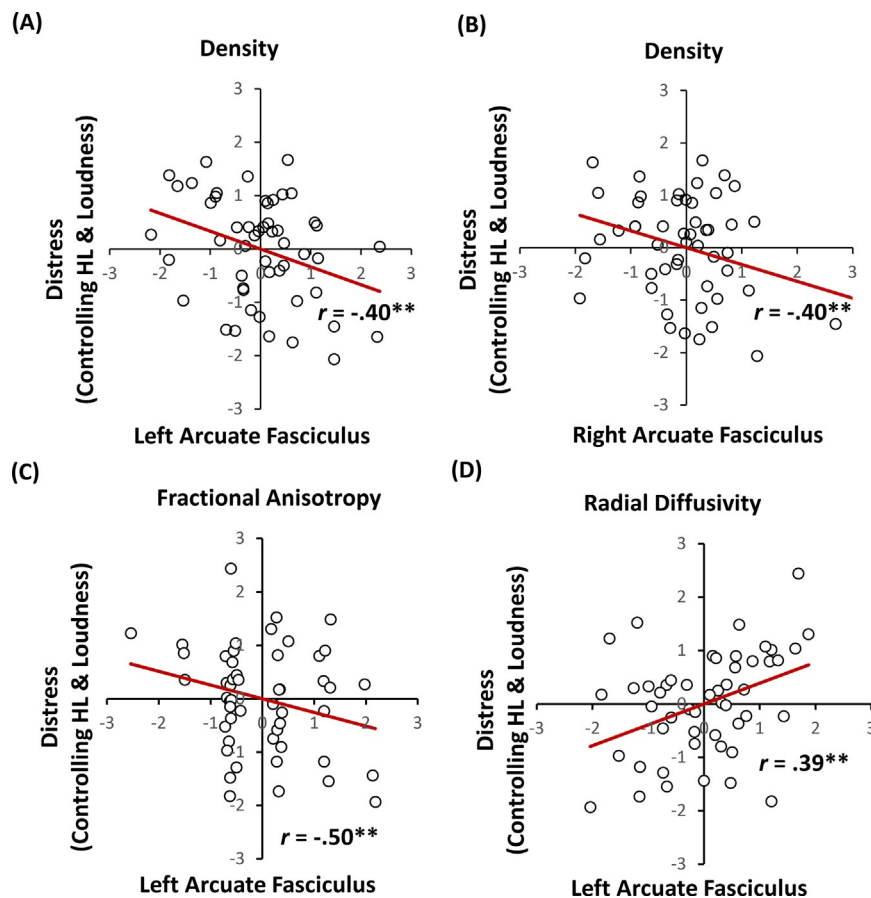


FIG. 4

Partial correlation for tract density (A) between left arcuate fasciculus and distress controlling for mean hearing loss and loudness; (B) right arcuate fasciculus and distress controlling for mean hearing loss and loudness; (C) left acoustic radiation and mean hearing loss controlling for distress and loudness; (D) right acoustic radiation and mean hearing loss controlling for distress and loudness.

Table 2 Partial correlation between arcuate fasciculus (AF), acoustic radiation (AR) tract density and distress controlling for hearing loss (HL) and loudness, HL controlling for distress and loudness, loudness controlling for distress and HL.

Tracts	Density and distress (controlling for HL and loudness)	Density and HL (controlling for distress and loudness)	Density and loudness (controlling for distress and HL)
AF left	$r = -0.40$ $P = 0.002$	$r = -0.11$ $P = 0.47$	$r = 0.07$ $P = 0.62$
AF right	$r = -0.40$ $P = 0.002$	$r = -0.03$ $P = 0.85$	$r = 0.15$ $P = 0.30$
AR left	$r = 0.04$ $P = 0.79$	$r = -0.34$ $P = 0.002$	$r = -0.18$ $P = 0.21$
AR right	$r = 0.04$ $P = 0.79$	$r = -0.33$ $P = 0.002$	$r = -0.13$ $P = 0.38$

Bold represents statistically significant at $P < 0.004$.

Table 3 Partial correlation between arcuate fasciculus (AF) and distress controlling for hearing loss (HL) and loudness, HL controlling for distress and loudness, loudness controlling for HL and distress.

Tracts	Distress (controlling for HL and Loudness)			HL (controlling for distress and loudness)			Loudness (controlling for HL, distress)		
	AD	RD	FA	AD	RD	FA	AD	RD	FA
AF left	$r=0.23$ $P=0.08$	$r=0.39$ $P=0.002$	$r=-0.50$ $P=0.003$	$r=-0.25$ $P=0.08$	$r=-0.35$ $P=0.01$	$r=-0.05$ $P=0.74$	$r=0.004$ $P=0.98$	$r=-0.02$ $P=0.92$	$r=0.19$ $P=0.18$
AF right	$r=0.16$ $P=0.27$	$r=0.36$ $P=0.016$	$r=-0.04$ $P=0.74$	$r=0.15$ $P=0.29$	$r=-0.24$ $P=0.10$	$r=-0.08$ $P=0.56$	$r=0.25$ $P=0.08$	$r=-0.19$ $P=0.18$	$r=-0.06$ $P=0.67$

AF, arcuate fasciculus; AD, axial diffusivity; RD, radial diffusivity; FA, fractional anisotropy. Bold represents the statistically significant at $P < 0.008$.

For hearing loss, no significant correlation was observed with FA of left nor right acoustic radiation after controlling for age and loudness. Also, for loudness, no significant correlation was observed with FA of the left acoustic radiation or the right acoustic radiation after controlling for hearing loss and age. For age, no significant correlation was observed with FA of the left nor right acoustic radiation values after controlling for hearing loss and loudness. See [Table 4](#) for an overview.

A significant correlation was observed between RD of the left acoustic radiation and hearing loss ($r=0.41$, $P=0.002$). For RD of the right acoustic radiation and hearing loss, no significant correlation was obtained after controlling for age and loudness. No significant correlation was observed between RD of the left nor right acoustic radiation and loudness after controlling for hearing loss and age. In addition, no significant correlation was observed between RD of the left acoustic radiation and age and right acoustic radiation and age after controlling for hearing loss and loudness. See [Table 4](#) for an overview.

No significant correlation was observed between AD of the left nor right acoustic radiation and hearing loss after controlling for age and loudness. No significant correlation was observed between AD of the left nor right acoustic radiation and loudness after controlling for hearing loss and age. In addition, no significant correlation was observed between AD of the left nor right acoustic radiation and age after controlling for hearing loss and loudness. See [Table 4](#) for an overview.

6 Discussion

In this study, we analyzed the influence of tract density, FA (white matter integrity), AD (axonal degeneration), and RD (demyelination) in the arcuate fasciculus and acoustic radiation. This study demonstrates that white matter changes are present in both tracts. Behavioral measures furthermore demonstrate that left arcuate fasciculus changes are correlated with tinnitus distress, and that left and right acoustic radiation changes are correlated to hearing loss after correcting for multicollinear factors.

The results of this study suggest reduced tract density in the left and right arcuate fasciculus as well as the left and right acoustic radiation tracts in tinnitus patients in comparison to controls. A possible cause for these alterations could be the loss of myelin sheath and axonal degeneration. This possibility is further bolstered by the increase in RD together with no change in AD and reduction in FA ([Winklewski et al., 2018](#)) a pattern also found in patients with schizophrenia ([Gómez-Gastiasoro et al., 2019](#)). The potential to detect and differentiate between axon degeneration and demyelination has been shown both in animal and human DTI studies ([Lin et al., 2008](#); [Song et al., 2003](#)). The integrity of the compacted, multilamellar myelin sheath plays an important role in determining the speed of neural transmission in the auditory cortex ([Huxley and Stämpeli, 1949](#); [Kimura and Itami, 2009](#); [Seidl et al., 2014](#); [Waxman, 1980](#)). Noise overexposure and aging trigger morphological changes

Table 4 Partial correlation between acoustic radiation (AR) and hearing loss (HL) controlling for age and loudness, loudness controlling for HL and age, age (controlling for HL and loudness).

Tracts	HL (controlling for age and loudness)			Loudness (controlling for HL and age)			Age (controlling for HL and loudness)		
	AD	RD	FA	AD	RD	FA	AD	RD	FA
AR left	$r=0.11$ $P=0.47$	$r=0.41$ $P=0.002$	$r=-0.25$ $P=0.07$	$r=0.09$ $P=0.56$	$r=0.34$ $P=0.018$	$r=0.15$ $P=0.32$	$r=-0.09$ $P=0.52$	$r=0.04$ $P=0.81$	$r=0.19$ $P=0.18$
AR right	$r=-0.01$ $P=0.96$	$r=0.29$ $P=0.046$	$r=-0.24$ $P=0.11$	$r=0.10$ $P=0.51$	$r=0.31$ $P=0.028$	$r=0.08$ $P=0.599$	$r=-0.01$ $P=0.98$	$r=-0.01$ $P=0.99$	$r=0.20$ $P=0.18$

AR: Acoustic Radiation; AF: AD: Axial diffusivity; RD: Radial Diffusivity; FA: Fractional Anisotropy. Bold represents the statistically significant at $P < 0.008$

in auditory nerve myelin subdomains such as nodes, paranodes, and juxtaparanodes exhibiting decreases in myelin thickness, leading to decreased action potentials and reduced conduction velocity (Poliak and Peles, 2003). This suggests that auditory nerve demyelination can lead to hearing dysfunction and associated tinnitus related to deficits of action potential propagation and the synaptic transmission in the auditory pathways (Tagoe et al., 2014; Zeng et al., 2005).

The changes in white matter properties in tinnitus patients are better understood by examining their relationship with behavioral variables. A positive association between demyelination and tinnitus distress and a negative association between white matter integrity and axonal degenerations and tinnitus distress was observed for the left arcuate fasciculus after controlling for hearing loss and tinnitus loudness. The lateral frontal lobe is substantially connected with the insula directly or indirectly via multiple connections with frontoparietal and opercular areas (Cipolloni and Pandya, 1999), both directly and via relay with the amygdala (Joseph, 2013; Romanski and LeDoux, 1993). In turn, the insula is extensively connected with the amygdala, which is the central integrator of emotional inputs (Augustine, 1996; Mega et al., 1997; Mesulam and Mufson, 1982). Furthermore, research has suggested that left arcuate fasciculus is associated with a patient's mood and somatic complaints in primary depression, multiple sclerosis and mild traumatic brain injury (Pujol et al., 1997, 2000; Spitz et al., 2017). Distress can also occur with white matter changes as reflected by decrease in density as well as reduction in the processing speed due to demyelination and reduction in integrity of frontal association fibers in the arcuate fasciculus (Felten et al., 2015; Pujol et al., 2000). These findings agree with the findings of the current study for tinnitus distress. It is important to note here that previous tinnitus studies fail to consistently show these results. Some studies show a negative correlation between reduced FA in the amygdala-hippocampal circuit and prefrontal cortex with THI and BDI scores respectively (Gunbey et al., 2017; Ryu et al., 2016), whereas some studies show no correlation with the emotional component of tinnitus (Aldhafeeri et al., 2012; Schmidt et al., 1679). Furthermore, tinnitus distress has been shown to be correlated with loudness and loudness with hearing loss (Vanneste et al., 2013; Goyal and Gupta, 2015). Thus, removing the contributing variance of the two factors we can disentangle the correlates of tinnitus distress alone.

For the left acoustic radiation, we observe a relationship between demyelination (RD) in addition to changes in tract density and hearing loss. The acoustic radiation conveys auditory information from the medial geniculate body of the thalamus to the auditory cortex (Maffei et al., 2018). In animals, it is known that hearing loss can result from dysfunction of cochlear hair cells, loss of auditory nerve afferent synapses, dysfunction of non-sensory cells that establish the endocochlear potential (Dubno et al., 2013), as well as the loss of spiral ganglion neurons (Sergeyenko et al., 2013). Animal studies have further demonstrated both acute and progressive spiral ganglion axon demyelination associated with hearing loss, even in the absence of soma death, and corresponding altered physiology following sensorineural deafening (Resnick et al., 2018). In these cases, the afferent signals from the auditory

pathway are greatly reduced and disordered. The data of this study suggest that demyelination of the acoustic radiation may inhibit the ability of the medial geniculate body to achieve central gain by not enabling to make homeostatic changes, worsening tinnitus (Casparly and Llano, 2017). Indeed, animal studies have shown that overexposure of noise induces alterations in myelin at and around the nodes of Ranvier that can likely impair the auditory brainstem response by decreasing the conduction velocity and conduction block (Mao et al., 2012; Tagoe et al., 2014) and induce tinnitus by changing central gain (Noreña, 2011; Roberts et al., 2010). Furthermore, given the high multicollinearity between age, tinnitus loudness and hearing loss (Gates and Mills, 2005; Goyal and Gupta, 2015; Huang and Tang, 2010), we show that this effect remains even after controlling for age and tinnitus loudness supporting the exclusivity of the effect to hearing loss.

We however do not see any correlation between tinnitus loudness and the different characteristics of white matter integrity in tinnitus after controlling for hearing loss. Previous studies support this finding showing that structural changes in the brain relate to the hearing loss rather than the tinnitus loudness itself (Melcher et al., 2013; Yoo et al., 2016). Furthermore, tinnitus loudness may be a functional aspect of the disorder which may be better captured by functional imaging techniques such as EEG, MEG and fMRI. It is widely agreed that tinnitus loudness is correlated with the amount of gamma activity and subsequently the intensity of BOLD activity in the auditory cortex (Chun-li et al., 2010; Van Der Loo et al., 2009). This has been replicated by several groups and has been verified by invasive and non-invasive neuromodulation techniques that targeting this hyperactivity may be able to provide relief in tinnitus loudness for some people (De Ridder and Vanneste, 2015; Langguth et al., 2006; Weisz et al., 2014).

The data of this study show a left lateralization effect for both the arcuate fasciculus and acoustic radiation. An ongoing debate within the literature is if tinnitus is always generated unilaterally on the left side or in the auditory cortex contralateral to the hearing loss (De Ridder, 2010). Based on fMRI (Melcher et al., 2000; Smits et al., 2007), MEG (Llinas et al., 2005; Muhlneckel et al., 1998; Weisz et al., 2007), and EEG (Van Der Loo et al., 2009; Vanneste and De Ridder, 2016), is it assumed that the tinnitus generator is located in the contralateral auditory cortex (Smits et al., 2007). However, most positron emission tomography (PET) studies suggest that tinnitus is always generated in the left auditory cortex (Arnold et al., 1996; Eichhammer et al., 2007).

An important question is whether DTI is a useful technique for evaluating functional pathologies such as tinnitus. The main arguments against the use of DTI are the following. (1) After controlling for hearing loss, tinnitus loudness does not survive statistical correction for multiple comparisons. (2) Results are not reproducible between different centers. (3) It is yet unknown whether the observed correlations reflect causal relations or are purely epiphenomena. Moreover, we analyzed only the effect of selected clinical characteristics. Nevertheless, there are also some arguments in favor of the use of DTI for functional pathologies. (1) Results in different studies converge in the sense that white matter changes occur in brain areas already

implicated in tinnitus as demonstrated by functional imaging studies. (2) One center has been able to replicate its own results (Leaver et al., 2011; Muhlau et al., 2006). (3) It is possible that tinnitus subgroups with similar characteristics might differ in their underlying neurobiological mechanism (Moller, 2007).

The present study has some limitations worth noting. Firstly, interpreting deterministic tractography images is problematic due to the intrinsic unrealistic assumption of a homogeneous unidirectional population inside the voxels. Specific regions of the brain contain two or more differently orientated fibers within the same voxels (crossing, diverging, kissing fibers) leading to a potential bias in the estimation of fiber directions and pathways and abrupt termination of tracts (Alexander et al., 2001; Barrick and Clark, 2004; Wiegell et al., 2000). This can be minimized by adopting more sophisticated approaches including high angular resolution diffusion imaging (HARDI) and hybrid diffusion imaging (HDI) (Jansons and Alexander, 2003; Tuch et al., 2002). Secondly, we could not test the changes occurring over time within a group as the study design was not longitudinal. Some of the changes observed in this study may be due to age and/or overexposure to noise (which we do not have details about). We therefore cannot definitively claim that hearing loss itself causes these changes.

Imaging techniques such as DTI can provide quantitative analysis by RD and AD but fail to provide histopathological aspects. A human study using temporal bone specimens from donors demonstrated that demyelination is caused by loss of myelin basic protein (MBP) (Xing et al., 2012). If proven that demyelination worsens tinnitus, future tinnitus treatments will involve exploring techniques for white matter regeneration or remyelination. Remyelination is a potential approach to treat multiple sclerosis, as it repairs the damaged regions of the central nervous system. A wealth of new strategies in animal models that promote remyelination have led to several clinical trials to test new reparative therapies (Plemel et al., 2017).

In conclusion, changes in the auditory tracts due to demyelination can lead to functional changes in auditory networks implicated in tinnitus (De Ridder et al., 2014). Whereas changes in the auditory thalamocortical tracts seem to be related to hearing loss, alterations in the frontal and parietal cortices connected to the auditory cortex seem to affect the emotional aspects of tinnitus, such as distress. We further demonstrate the relationship between changes in white matter tracts and tinnitus symptoms after controlling for potential confounding variables which make the results of the current study more reliable than previous studies in tinnitus. Nevertheless, we observe that the changes in white matter properties seem to only encode the hearing loss and emotional component of the disorder and not the sensory component which we hypothesize is more a functional malfunctioning than structural.

Acknowledgment

We thank Srujan Esanakarra for his help with data processing.

Competing interests

None.

References

- Aldhafeeri, F.M., Mackenzie, I., Kay, T., Alghamdi, J., Sluming, V., 2012. Neuroanatomical correlates of tinnitus revealed by cortical thickness analysis and diffusion tensor imaging. *Neuroradiology* 54, 883–892.
- Alexander, A.L., Hasan, K.M., Lazar, M., Tsuruda, J.S., Parker, D.L., 2001. Analysis of partial volume effects in diffusion-tensor MRI. *Magn. Reson. Med.* 45, 770–780.
- Arnold, W., Bartenstein, P., Oestreich, E., Romer, W., Schwaiger, M., 1996. Focal metabolic activation in the predominant left auditory cortex in patients suffering from tinnitus: a PET study with [18F]deoxyglucose. *ORL J. Otorhinolaryngol. Relat. Spec.* 58, 195–199.
- Augustine, J.R., 1996. Circuitry and functional aspects of the insular lobe in primates including humans. *Brain Res. Rev.* 22, 229–244.
- Axelsson, A., Ringdahl, A., 1989. Tinnitus—a study of its prevalence and characteristics. *Br. J. Audiol.* 23, 53–62.
- Axelsson, A., Sandh, A., 1985. Tinnitus in noise-induced hearing loss. *Br. J. Audiol.* 19, 271–276.
- Barrick, T.R., Clark, C.A., 2004. Singularities in diffusion tensor fields and their relevance in white matter fiber tractography. *Neuroimage* 22, 481–491.
- Basser, P.J., Mattiello, J., LeBihan, D., 1994. Estimation of the effective self-diffusion tensor from the NMR spin echo. *J. Magn. Reson. B* 103, 247–254.
- Beaulieu, C., 2002. The basis of anisotropic water diffusion in the nervous system—a technical review. *NMR Biomed.* 15, 435–455.
- Benson, R.R., Gattu, R., Cacace, A.T., 2014. Left hemisphere fractional anisotropy increase in noise-induced tinnitus: a diffusion tensor imaging (DTI) study of white matter tracts in the brain. *Hear Res.* 309, 8–16. <https://doi.org/10.1016/j.heares.2013.10.005>. Epub 2013 Nov 8.
- Caspary, D.M., Llano, D.A., 2017. Auditory thalamic circuits and GABAA receptor function: putative mechanisms in tinnitus pathology. *Hear. Res.* 349, 197–207.
- Catani, M., Mesulam, M., 2008. The arcuate fasciculus and the disconnection theme in language and aphasia: history and current state. *Cortex* 44 (8), 953–961. <https://doi.org/10.1016/j.cortex.2008.04.002>. Epub 2008 May 23.
- Chanraud, S., Zahr, N., Sullivan, E.V., Pfefferbaum, A., 2010. MR diffusion tensor imaging: a window into white matter integrity of the working brain. *Neuropsychol. Rev.* 20, 209–225.
- Chun-li, M., Xian-ming, C., Zi-qian, C., You-qiang, Y., Ping, L.U.O., 2010. BOLD-fMRI study of auditory cortex in patients with tinnitus. *J. Otol.* 5, 46–50.
- Cipolloni, P., Pandya, D., 1999. Cortical connections of the frontoparietal opercular areas in the rhesus monkey. *J Comp Neurol* 403, 431–458.
- Crippa, A., Lanting, C.P., Van Dijk, P., Roerdink, J.B.T.M., 2010. A diffusion tensor imaging study on the auditory system and tinnitus. *Open Neuroimag. J.* 4, 16–25. <https://doi.org/10.2174/1874440001004010016>.
- De Ridder, D., 2010. Should rTMS for tinnitus be performed left-sided, ipsilaterally or contralaterally, and is it a treatment or merely investigational? *Eur. J. Neurol.* 17, 891–892.

- De Ridder, D., Vanneste, S., 2015. Multitarget surgical neuromodulation: combined C2 and auditory cortex implantation for tinnitus. *Neurosci. Lett.* 591, 202–206.
- De Ridder, D., Vanneste, S., Weisz, N., Londero, A., Schlee, W., Elgoyhen, A.B., et al., 2014. An integrative model of auditory phantom perception: tinnitus as a unified percept of interacting separable subnetworks. *Neurosci. Biobehav. Rev.* 44, 16–32.
- Dubno, J.R., Eckert, M.A., Lee, F.-S., Matthews, L.J., Schmiedt, R.A., 2013. Classifying human audiometric phenotypes of age-related hearing loss from animal models. *J. Assoc. Res. Otolaryngol.* 14, 687–701.
- Eichhammer, P., Hajak, G., Kleinjung, T., Landgrebe, M., Langguth, B., 2007. Functional imaging of chronic tinnitus: the use of positron emission tomography. *Prog. Brain Res.* 166, 83–88.
- Felten, D.L., O'Banion, M.K., Maida, M.S., 2015. *Netter's Atlas of Neuroscience*. Elsevier Health Sciences.
- Gates, G.A., Mills, J.H., 2005. Presbycusis. *Lancet* 366, 1111–1120.
- Gómez-Gastiasoro, A., Zubiaurre-Elorza, L., Peña, J., Ibarretxe-Bilbao, N., Rilo, O., Schretlen, D.J., et al., 2019. Altered frontal white matter asymmetry and its implications for cognition in schizophrenia: a tractography study. *Neuroimage Clin.* 22, 101781.
- Goyal, D., Gupta, N., 2015. Study of correlation of tinnitus and sensorineural hearing loss. *J. Adv. Med. Dent. Sci. Res.* 3, 11.
- Gunbey, H., Gunbey, E., Aslan, K., Bulut, T., Unal, A., Incesu, L., 2017. Limbic-auditory interactions of tinnitus: an evaluation using diffusion tensor imaging. *Clin. Neuroradiol.* 27, 221–230.
- Huang, Q., Tang, J., 2010. Age-related hearing loss or presbycusis. *Eur. Arch. Otorhinolaryngol.* 267, 1179–1191.
- Huxley, A., Stämpeli, R., 1949. Evidence for saltatory conduction in peripheral myelinated nerve fibres. *J. Physiol.* 108, 315–339.
- Jansons, K.M., Alexander, D.C., 2003. Persistent angular structure: new insights from diffusion magnetic resonance imaging data. *Inverse Prob.* 19, 1031.
- Jastreboff, P.J., 1990. Phantom auditory perception (tinnitus): mechanisms of generation and perception. *Neurosci. Res.* 8, 221–254.
- Joseph, R., 2013. *Neuropsychology, Neuropsychiatry, and Behavioral Neurology*. Springer Science & Business Media.
- Kimura, F., Itami, C., 2009. Myelination and isochronicity in neural networks. *Front. Neuroanat.* 3, 12.
- Langguth, B., Eichhammer, P., Kreutzer, A., Maenner, P., Marienhagen, J., Kleinjung, T., et al., 2006. The impact of auditory cortex activity on characterizing and treating patients with chronic tinnitus—first results from a PET study. *Acta Otolaryngol.* 126, 84–88.
- Langguth, B., Kreuzer, P.M., Kleinjung, T., De Ridder, D., 2013. Tinnitus: causes and clinical management. *Lancet Neurol.* 12, 920–930.
- Lau, P., Wollbrink, A., Wunderlich, R., Engell, A., Löhe, A., Junghöfer, M., et al., 2018. Targeting heterogeneous findings in neuronal oscillations in tinnitus: analyzing MEG novices and mental health comorbidities. *Front. Psychol.* 9, 235.
- Leaver, A.M., Renier, L., Chevillet, M.A., Morgan, S., Kim, H.J., Rauschecker, J.P., 2011. Dysregulation of limbic and auditory networks in tinnitus. *Neuron* 69, 33–43.
- Leaver, A.M., Seydell-Greenwald, A., Turesky, T., Morgan, S., Kim, H.J., Rauschecker, J.P., 2012. Cortico-limbic morphology separates tinnitus from tinnitus distress. *Front. Syst. Neurosci. Front. Syst. Neurosci.* 6, 21.

- Lin, Y., Wang, J., Wu, C., Wai, Y., Yu, J., Ng, S., 2008. Diffusion tensor imaging of the auditory pathway in sensorineural hearing loss: changes in radial diffusivity and diffusion anisotropy. *J. Magn. Reson. Imaging* 28, 598–603.
- Llinas, R., Urbano, F.J., Leznik, E., Ramirez, R.R., van Marle, H.J., 2005. Rhythmic and dysrhythmic thalamocortical dynamics: GABA systems and the edge effect. *Trends Neurosci.* 28, 325–333.
- Maffei, C., Jovicich, J., De Benedictis, A., Corsini, F., Barbareschi, M., Chioffi, F., et al., 2018. Topography of the human acoustic radiation as revealed by ex vivo fibers micro-dissection and in vivo diffusion-based tractography. *Brain Struct. Funct.* 223, 449–459.
- Mao, J.C., Pace, E., Pierozynski, P., Kou, Z., Shen, Y., VandeVord, P., et al., 2012. Blast-induced tinnitus and hearing loss in rats: behavioral and imaging assays. *J. Neurotrauma* 29, 430–444.
- Maudoux, A., Lefebvre, P., Cabay, J.E., Demertzi, A., Vanhauzenhuysse, A., Laureys, S., et al., 2012. Connectivity graph analysis of the auditory resting state network in tinnitus. *Brain Res.* 1485, 10–21.
- Mega, M.S., Cummings, J.L., Salloway, S., Malloy, P., 1997. The limbic system: an anatomic, phylogenetic, and clinical perspective. *J. Neuropsychiatry Clin. Neurosci.* 9, 315–330.
- Melcher, J.R., Sigalovsky, I.S., Guinan Jr., J.J., Levine, R.A., 2000. Lateralized tinnitus studied with functional magnetic resonance imaging: abnormal inferior colliculus activation. *J. Neurophysiol.* 83, 1058–1072.
- Melcher, J.R., Knudson, I.M., Levine, R.A., 2013. Subcallosal brain structure: correlation with hearing threshold at supra-clinical frequencies (> 8 kHz), but not with tinnitus. *Hear. Res.* 295, 79–86.
- Mesulam, M., Mufson, E.J., 1982. Insula of the old world monkey. III: efferent cortical output and comments on function. *J. Comp. Neurol.* 212, 38–52.
- Moller, A.R., 2007. Tinnitus: presence and future. *Prog. Brain Res.* 166, 3–16.
- Muhlau, M., Rauschecker, J.P., Oestreicher, E., Gaser, C., Rottinger, M., Wohlschlagel, A.M., et al., 2006. Structural brain changes in tinnitus. *Cereb. Cortex* 16, 1283–1288.
- Muhn timer, W., Elbert, T., Taub, E., Flor, H., 1998. Reorganization of auditory cortex in tinnitus. *Proc. Natl. Acad. Sci. U. S. A.* 95, 10340–10343.
- Neil, J., Miller, J., Mukherjee, P., Hüppi, P.S., 2002. Diffusion tensor imaging of normal and injured developing human brain—a technical review. *NMR Biomed.* 15, 543–552.
- Noreña, A.J., 2011. An integrative model of tinnitus based on a central gain controlling neural sensitivity. *Neurosci. Biobehav. Rev.* 35, 1089–1109.
- Papadakis, N.G., Xing, D., Houston, G.C., Smith, J.M., Smith, M.I., James, M.F., et al., 1999. A study of rotationally invariant and symmetric indices of diffusion anisotropy. *Magn. Reson. Imaging* 17, 881–892.
- Pierpaoli, C., Basser, P.J., 1996. Toward a quantitative assessment of diffusion anisotropy. *Magn. Reson. Med.* 36, 893–906.
- Plemel, J.R., Liu, W.-Q., Yong, V.W., 2017. Remyelination therapies: a new direction and challenge in multiple sclerosis. *Nat. Rev. Drug Discov.* 16, 617.
- Poliak, S., Peles, E., 2003. The local differentiation of myelinated axons at nodes of Ranvier. *Nat. Rev. Neurosci.* 4, 968.
- Pujol, J., Bello, J., Deus, J., Martí-Vilalta, J., Capdevila, A., 1997. Lesions in the left arcuate fasciculus region and depressive symptoms in multiple sclerosis. *Neurology* 49, 1105–1110.
- Pujol, J., Bello, J., Deus, J., Cardoner, N.S., Martí-Vilalta, J.L., Capdevila, A., 2000. Beck depression inventory factors related to demyelinating lesions of the left arcuate fasciculus region. *Psychiatry Res. Neuroimaging* 99, 151–159.

- Resnick, J.M., O'Brien, G.E., Rubinstein, J.T., 2018. Simulated auditory nerve axon demyelination alters sensitivity and response timing to extracellular stimulation. *Hear. Res.* 361, 121–137.
- Richardson, B.D., Brozoski, T.J., Ling, L.L., Caspary, D.M., 2012. Targeting inhibitory neurotransmission in tinnitus. *Brain Res.* 1485, 77–87.
- Roberts, L.E., Eggermont, J.J., Caspary, D.M., Shore, S.E., Melcher, J.R., Kaltenbach, J.A., 2010. Ringing ears: the neuroscience of tinnitus. *J. Neurosci.* 30, 14972–14979.
- Romanski, L.M., LeDoux, J.E., 1993. Information cascade from primary auditory cortex to the amygdala: corticocortical and corticoamygdaloid projections of temporal cortex in the rat. *Cereb. Cortex* 3, 515–532.
- Ryu, C.-W., Park, M.S., Byun, J.Y., Jahng, G.-H., Park, S., 2016. White matter integrity associated with clinical symptoms in tinnitus patients: a tract-based spatial statistics study. *Eur. Radiol.* 26, 2223–2232.
- Salviati, M., Bersani, F.S., Valeriani, G., Minichino, A., Panico, R., Romano, G.F., et al., 2014. A brain centred view of psychiatric comorbidity in tinnitus: from otology to hodology. *Neural Plast.* 2014, 817852.
- Schmidt, S.A., Zimmerman, B., Medina, R.O.B., Carpenter-Thompson, J.R., Husain, F.T., 2018. Changes in gray and white matter in subgroups within the tinnitus population. *Brain Res.* 1679, 64–74.
- Seidl, A.H., Rubel, E.W., Barría, A., 2014. Differential conduction velocity regulation in ipsilateral and contralateral collaterals innervating brainstem coincidence detector neurons. *J. Neurosci.* 34, 4914–4919.
- Sergeyenko, Y., Lall, K., Liberman, M.C., Kujawa, S.G., 2013. Age-related cochlear synaptopathy: an early-onset contributor to auditory functional decline. *J. Neurosci.* 33, 13686–13694.
- Seydell-Greenwald, A., Raven, E.P., Leaver, A.M., Turesky, T.K., Rauschecker, J.P., 2014. Diffusion imaging of auditory and auditory-limbic connectivity in tinnitus: preliminary evidence and methodological challenges. *Neural Plast.* 2014, 145943.
- Smits, M., Kovacs, S., de Ridder, D., Peeters, R.R., van Hecke, P., Sunaert, S., 2007. Lateralization of functional magnetic resonance imaging (fMRI) activation in the auditory pathway of patients with lateralized tinnitus. *Neuroradiology* 49, 669–679.
- Song, S.-K., Sun, S.-W., Ramsbottom, M.J., Chang, C., Russell, J., Cross, A.H., 2002. Demyelination revealed through MRI as increased radial (but unchanged axial) diffusion of water. *Neuroimage* 17, 1429–1436.
- Song, S.-K., Sun, S.-W., Ju, W.-K., Lin, S.-J., Cross, A.H., Neufeld, A.H., 2003. Diffusion tensor imaging detects and differentiates axon and myelin degeneration in mouse optic nerve after retinal ischemia. *Neuroimage* 20, 1714–1722.
- Spitz, G., Alway, Y., Gould, K.R., Ponsford, J.L., 2017. Disrupted white matter microstructure and mood disorders after traumatic brain injury. *J. Neurotrauma* 34, 807–815.
- Tagoe, T., Barker, M., Jones, A., Allcock, N., Hamann, M., 2014. Auditory nerve perinodal dysmyelination in noise-induced hearing loss. *J. Neurosci.* 34, 2684–2688.
- Tuch, D.S., Reese, T.G., Wiegell, M.R., Makris, N., Belliveau, J.W., Wedeen, V.J., 2002. High angular resolution diffusion imaging reveals intravoxel white matter fiber heterogeneity. *Magn. Reson. Med.* 48, 577–582.
- Ulmer, J.L., Biswal, B.B., Mark, L.P., Mathews, V.P., Prost, R.W., Millen, S.J., et al., 1998. Acoustic echoplanar scanner noise and pure tone hearing thresholds: the effects of sequence repetition times and acoustic noise rates. *J. Comput. Assist. Tomogr.* 22, 480–486.

- Van Der Loo, E., Gais, S., Congedo, M., Vanneste, S., Plazier, M., Menovsky, T., et al., 2009. Tinnitus intensity dependent gamma oscillations of the contralateral auditory cortex. *PLoS One* 4, , e7396.
- van Pul, C., Buijs, J., Janssen, M.J., Roos, G.F., Vlaardingerbroek, M.T., Wijn, P.F., 2005. Selecting the best index for following the temporal evolution of apparent diffusion coefficient and diffusion anisotropy after hypoxic-ischemic white matter injury in neonates. *Am. J. Neuroradiol.* 26, 469–481.
- Vanneste, S., De Ridder, D., 2016. Deafferentation-based pathophysiological differences in phantom sound: Tinnitus with and without hearing loss. *Neuroimage* 129, 80–94.
- Vanneste, S., Plazier, M., Ev, D.L., De Heyning, P.V., Congedo, M., De Ridder, D., 2010. The neural correlates of tinnitus-related distress. *Neuroimage* 52, 470–480.
- Vanneste, S., Congedo, M., De Ridder, D., 2013. Pinpointing a highly specific pathological functional connection that turns phantom sound into distress. *Cereb. Cortex* 24, bht068.
- Vilanova, A., Zhang, S., Kindlmann, G., Laidlaw, D., 2006. An introduction to visualization of diffusion tensor imaging and its applications. In: *Visualization and Processing of Tensor Fields*. Springer, pp. 121–153.
- Wang, J.J., Tc, C., Wai, Y.Y., Hsu, Y., 2006. Novel diffusion anisotropy indices: an evaluation. *J. Magn. Reson. Imaging* 24, 211–217.
- Waxman, S.G., 1980. Determinants of conduction velocity in myelinated nerve fibers. *Muscle Nerve* 3, 141–150.
- Weisz, N., Muller, S., Schlee, W., Dohrmann, K., Hartmann, T., Elbert, T., 2007. The neural code of auditory phantom perception. *J. Neurosci.* 27, 1479–1484.
- Weisz, N., Lüchinger, C., Thut, G., Müller, N., 2014. Effects of individual alpha rTMS applied to the auditory cortex and its implications for the treatment of chronic tinnitus. *Hum. Brain Mapp.* 35, 14–29.
- Wiegell, M.R., Larsson, H.B., Wedeen, V.J., 2000. Fiber crossing in human brain depicted with diffusion tensor MR imaging. *Radiology* 217, 897–903.
- Winklewski, P.J., Sabisz, A., Naumczyk, P., Jodzio, K., Szurowska, E., Szarmach, A., 2018. Understanding the physiopathology behind axial and radial diffusivity changes-what do we know? *Front. Neurol.* 9, 92.
- Xing, Y., Samuvel, D.J., Stevens, S.M., Dubno, J.R., Schulte, B.A., Lang, H., 2012. Age-related changes of myelin basic protein in mouse and human auditory nerve. *PLoS One* 7, , e34500.
- Yoo, H.B., De Ridder, D., Vanneste, S., 2016. White matter changes in tinnitus: is it all age and hearing loss? *Brain Connect.* 6, 84–93.
- Zeng, F.-G., Kong, Y.-Y., Michalewski, H.J., Starr, A., 2005. Perceptual consequences of disrupted auditory nerve activity. *J. Neurophysiol.* 93, 3050–3063.